



The Etiology, Diagnosis and Treatment of Differentiated Thyroid Carcinoma in Children and Adolescents

Jiangqiao Geng^{1,2}, Jun Tai^{1,2}, Bojun Wei³, Yongli Guo², Xin Ni^{1,2*}

¹Department of Otolaryngology, Head and Neck Surgery, Beijing Children's Hospital, Capital Medical University, Beijing, PR China.

²Beijing Key Laboratory for Pediatric Diseases of Otolaryngology, Head and Neck Surgery, Beijing Pediatric Research Institute, Beijing Children's Hospital, Capital Medical University, Beijing, PR China.

³Department of Otolaryngology, Head and Neck Surgery, Beijing Shijitan's Hospital, Capital Medical University, Beijing, PR China.

***Corresponding author:**

Xin Ni, Ph. D.

Department of Otolaryngology

Head and Neck Surgery

Beijing Children's Hospital

Capital Medical University

Beijing 100045, PR. China

Tel: 0086-010-59616896

Email: nixin@bch.com.cn

Received: 21 October 2014; | Revised: 18 November 2014; | Accepted: 18 December 2014

Abstract

Differentiated thyroid carcinoma (DTC) of epithelium origin in children and adolescents is an uncommon malignancy with an excellent prognosis. However, pediatric DTC always presents at advanced stages and with higher rates of recurrence. This review aims at the current findings of etiology, diagnosis and therapeutic approach for pediatric DTC. Radiation exposure is the only established risk of pediatric DTC, which was first discovered more than half a century ago. Research uncovers family history of thyroid carcinoma and nonthyroid malignant tumors may also be a risk factor in children DTC. Conventional diagnostic methods including palpation, ultrasonography and fine needle aspiration cytology (FNAC), may provide definitive diagnoses for many patients. For patients cannot be confirmed, molecular markers such as BRAF V600E and RAS mutations as well as RET-PTC rearrangements maybe improved diagnosis of thyroid nodules. Although recurrence is common, the outcome is favorable when appropriately treated. To minimize the risk of recurrence, total thyroidectomy, central compartment dissection, with or without lateral compartment dissection should be the surgical procedure for most pediatric DTC. Furthermore, suppression of serum thyroid stimulating hormone, radioactive iodine therapy for remnant ablation and a long-term follow-up should be done for most pediatric DTC.

Keywords: Differentiated Thyroid Carcinoma, Fine Needle Aspiration Cytology, Thyroidectomy, Radioactive Iodine.

1. Introduction

The incidence of thyroid carcinoma (TC), the most common endocrine malignancy of the head and neck, has dramatically increased in recent decades [1]. In the United States, the average annual increase in TC occurrence is the highest among all malignant tumors between 2000 and 2009 partly owing to the improvement of diagnostic techniques. Based on the histological types, TC can be classified as papillary, follicular, medullary, anaplastic thyroid carcinoma and other rare categories [2]. Papillary and follicular types are differentiated thyroid carcinomas (DTC), which account for > 90% of all thyroid carcinomas in both children and adults [3].

For children, the annual increase rate is 1.1 % in the incidence of TC over the 31 years study period [4]. A recent study summarizing the DTC incidence rate in the USA from 1984 to 2010 showed that the DTC in children (0-14 years) is 1.11 per million, much lower than that in older (15-29 years) population which is 34.56 per million [5]. Despite of the lower occurrence and death rate in children and adolescences, the DTC recurrence frequency is much higher than that in adults and 8%-50% of thyroid nodules are malignant [6, 7]. The pediatric DTC commonly present with larger painless palpable thyroid and/or neck lumps and is readily neglected. Therefore, often time, the disease has developed to its advanced stages in the very first admission when the clinical presentation becomes obvious enough for patients' attention. Some severe patients present with dysphagia, cough, hoarseness, airway obstruction or even distant metastasis to lung or bone at the time of diagnosis. Despite of delayed diagnosis, the death rate and risk of DTC recurrence could be minimized with proper treatments [4, 5, 8, 9].

2. Etiology

Radiation exposure is an established risk of pediatric DTC, which was first discovered more than half a century ago in children treated for tinea capitis and acne with irradiation [10, 11]. Recently, a British study showed that thyroid second primary malignancy can develop after exposure to radiotherapy and the risk of TC was highest in patients treated for Hodgkin's disease and Non Hodgkin's Lymphoma [12]. Radiation exposure as a risk factor for pediatric DTC have ascertained after the atomic blasts in Japan, Chernobyl and Fukushima disasters [13-16]. As of September 2013, 59 children had been diagnosed with TC by fine needle aspiration cytology (FNAC) out of the 360,000 Japanese children lived in the area at the time of the Fukushima nuclear leakage in 2011 [16]. Diagnostic radiation such as pelvimetry and childhood computed tomography (CT) has also been linked with increased incidence of pediatric DTC. So physicians should limit CT scanning in children and protect the thyroid when cervical CT scans are unavoidable [17].

Recently, the genetic alteration of DTC is receiving much attention. Some genetic syndromes such as Werner syndrome caused by a mutation in the WRN gene, Gardner syndrome caused by mutation in chromosome 5q21 and Cowden syndrome caused by mutation in the PTEN gene are proved associated with thyroid carcinoma. The congenital hypothyroidism caused by mutations in the TPO gene is also proved can lead to DTC. These patients most likely have a susceptibility gene that increases the risk of thyroid cancer [18]. However, patients with these familial syndromes are rare. For the majority of patients, BRAF V600E mutation, RAS mutation and RET/PTC rearrangement are the fundamental roles in the tumorigenesis of DTC. BRAF V600E mutation belongs to the family of RAF and activates the mitogen-activated protein kinase (MAPK). The

importance of MAPK pathway has been well established in DTC, especially for PTC. The classical MAPK pathway is driven firstly by an extracellular mitogenic stimulus that activates a receptor tyrosine kinase (RTK) in the cellular membrane and in turn to active RAS, BRAF, MEK and ERK. Activated ERK enters the nucleus and then upregulates tumor promoting genes and downregulates tumor suppressor genes [2, 19]. Recently, a study of pediatric PTC demonstrates that BRAF V600E mutations occur in 63% patients at a rate comparable to adults [20]. What is more meaningful is the gene mutation rarely appears in thyroid benign tumor and inflammatory diseases of the thyroid gland. RAS mutation is another prevailing mutation in DTC and often occurrences in follicular thyroid carcinoma. There are three subtypes of RAS: NRAS, KRAS and HRAS. NRAS seems to be a predominantly mutation in DTC and activates the PI3K–AKT pathway in thyroid tumorigenesis [21]. The PI3K–AKT pathway also has a fundamental role in DTC tumorigenesis and the function was initially revealed by the finding of increased expression and activation of AKT in DTC [22]. Extracellular signal activates RTK in the cell membrane, leading to the activation of RAS and subsequent activation of PI3K. Activated PI3K further phosphorylate AKT. Phosphorylated AKT, which is an activated form of AKT, enters the nucleus where it induces tumor-promoting genes and then leads to thyroid carcinoma cell growth and proliferation. RET/PTC rearrangements are more common in pediatric DTC than in adults. RET/PTC1 and RET/PTC3 rearrangements are the two main mutations which account for 80% of the RET/PTC rearrangements in DTC. RET/PTC1 rearrangement is more common in sporadic DTC and RET/PTC3 is more common in radiation-induced DTC.

Family history may also be a risk factor in children DTC. A European case-control study in children and adolescents indicated that papillary thyroid carcinoma (PTC) was significantly related to family history of thyroid carcinoma, residence in an endemic goiter area, benign thyroid disease and nonthyroid malignant tumors [23]. Nevertheless, the association of family

history with DTC remains to be determined due to the limited number of patients recruited in this study. In addition, environmental pollution and iodine in the diet is also thought associated with thyroid carcinoma.

3. Diagnostics

Current approaches such as palpation, ultrasonography and FNAC are able to provide definitive diagnoses for most of patients with some difficult cases not being confirmed [24, 25]. In additional, serum thyrotropic-stimulating hormone (TSH), thyroglobulin, thyroglobulin antibodies, free T4 and/or total T4 and free T3 and/or total T3 should be obtained when thyroid nodules are detected. However, these parameters only play a supplementary role with low sensitivities and specificities in the diagnosis of thyroid carcinoma.

Thyroid nodule is an alarming sign for the diagnosis of pediatric DTC. Palpation is one of the primary approaches of diagnosis for pediatric DTC. Unfortunately this approach is largely depending on physician's experience. In view of this, thyroid ultrasonography should be performed for patients with suspected thyroid carcinoma, thyroid nodules, or persistent enlarged cervical lymph nodes. Ultrasonography is a useful tool to detect lateral cervical lymph nodes and assure the accuracy of lymph node dissection. Nodule height greater than width, microcalcifications, absent halo sign, increased intranodular vascularity, hypoechogenicity, solid nodule structure, irregularity and variable echotexture are considered to be the specific ultrasonography characteristics of thyroid carcinoma in adults [26, 27]. In children the most reliable ultrasound diagnostic criteria for DTC were irregular tumor outline, subcapsular location, and increased intranodular vascularization by Doppler technique [28]. Thyroid ultrasonography is currently the most accurate imaging modality for detecting DTC. However, it cannot reliably distinguish between benign thyroid nodules and malignant differentiated thyroid cancer [29, 30].

FNAC especially ultrasonography-guided FNAC is one of the most accurate diagnostic tests

for thyroid nodules in children and adolescents. A good concordance between FNAC and surgical biopsies has been proved in children and adolescents [24, 25]. A recent meta-analysis showed sensitivity and specificity of FNAC in predicting malignancy were 94% (95% CI, 86%-100%) and 81% (95% CI, 72%-91%), respectively [7]. The preoperative FNAC assessment has substantially reduced the number of patients otherwise being assigned to diagnostic surgery after which being proved to be benign. Therefore, a FNAC should be carried out when a child with a thyroid nodule was suspected for DTC. However, FNAC has its limitations in children since children are more susceptible to the discomfort making it difficult to constrain their position for the convenience of needle application. Thus, thyroid FNAC in children is often performed with sedation. In addition to, a study from the USA showed that a median of 17% (10–26%) of FNAC undertaken were indeterminate and 6% (1–11%) were non-diagnostic [31]. Most patients with an indeterminate or non-diagnostic FNAC specimen confused with whether they should undergo diagnostic surgery or watchful waiting. The question for these patients is whether other diagnostic techniques are available to help them make the right choices.

Fortunately, diagnosis based on gene detection becomes increasingly applicable. BRAF V600E mutations, RAS mutations, RET-PTC rearrangements and PAX8-PPAR γ rearrangements of FNA samples have been used for evaluate indeterminate or non-diagnostic thyroid nodules [32-35]. Nikiforov and colleagues have conducted the most large-scale prospective study so far, which used these four gene detections to investigate the clinical utility of molecular testing of thyroid FNA samples with indeterminate cytology [36]. The positive rate of any mutation conferred the risk of TC in suspicious for malignant cells, specific categories of indeterminate cytology and follicular neoplasm/suspicious for a follicular neoplasm was 95%, 88% and 87%, respectively. The risk of cancer in mutation-negative nodules was 28%, 6% and 14%, respectively. Among these molecular markers, BRAF mutation is the focus

of attention [32, 37-39]. BRAF mutation, which causes constitutive activation of the serine/threonine kinase has been demonstrated a strong association with extrathyroidal extension, advanced disease stages, lymph node metastasis and disease recurrence of PTC. However, the prevalence of the BRAF mutation in the pediatric PTC is variable from 3.2% to 63%, and the relationship between BRAF status and aggressive tumor behavior remains unclear in children and adolescents [20, 40]. It must be realized that understanding of the relevance between these genetic markers and pediatric DTC is very important for diagnosis, treatment planning, and targeted therapy.

4. Treatment

Since pediatric DTC is an aggressive disease with high recurrences, a perfect treatment plan to minimize the risk of recurrence and complications should be formulated. Appropriate operation scheme, radioactive iodine (RAI) therapy for remnant ablation and suppression of thyroid stimulating hormone (TSH) are helpful to achieve the purpose (Fig 1).

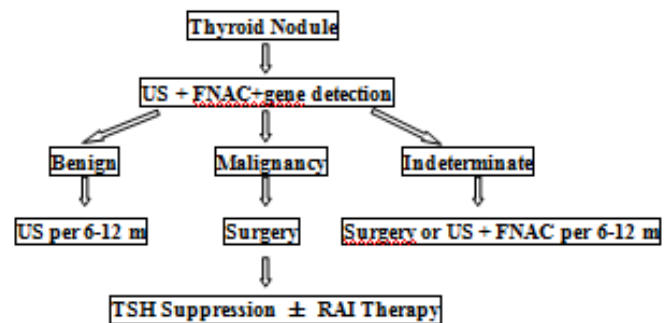


Fig 1. Diagnosis and treatment of pediatric DTC. US = ultrasonography, FNAC = fine needle aspiration cytology, TST = thyrotropic-stimulating hormone, RAI= radioactive iodine.

Surgery containing thyroid surgery and neck dissection is the cornerstone of treatment for pediatric DTC but the scope of surgical resection for pediatric patients is under debate. The two main options for thyroid surgery are hemithyroidectomy and total thyroidectomy (TT) [41, 42]. For hemithyroidectomy, the

contralateral parathyroid gland and the recurrent laryngeal nerve are intact. Thus, the incidence of postoperative hypoparathyroidism and recurrent laryngeal nerve paralysis significantly decreased. Hemithyroidectomy is favored for treatment of DTC which is unifocal and less than 1 cm in diameter by some experts. However most pediatric DTC are usually multifocal, bilateral and advanced at presentation, so TT was recommended for most children and adolescent patients (Table 1). In spite of no randomized controlled trials have examined which of the two surgical approaches is better so far, more and more experts advise TT [23, 43-46]. A recent study demonstrated that the patients with larger tumors, nodal metastases, higher family income as well as private insurance were more likely to undergo TT [43]. Proponents of TT note several key clinical advantages of the extensive surgical management. Firstly, pediatric DTC is commonly with a high proportion of multifocal and bilateral at the time of presentation thus TT should be more likely to remove all disease foci and minimize the need for reoperation. Secondly, the increased level of serum thyroglobulin for the patient with TT is a sensitive marker of disease recurrence. Thirdly, RAI remnant ablation can be used to treat and detect local and distant metastases if patients undergo TT. Of course, TT may be associated with higher surgical complications compared with hemithyroidectomy especially done by inexperienced surgeons [47].

Neck dissection is another important part of the surgical treatment includes central compartment dissection and lateral compartment dissection [42, 48]. Central compartment dissection is evidently needed for pediatric DTC with prelaryngeal, pretracheal or paratracheal lymph nodes involved. For pediatric DTC without obvious nodal involvement, prophylactic central compartment dissection may be considered for advanced tumor size and with extrathyroid extension [49]. For patients with low risk (unifocal microscopic thyroid carcinoma, without radiation exposure, without extrathyroidal extension or confirmed lymph-node metastases) the absolute benefits obtained from prophylactic central compartment dissection might be outweighed by other considerations.

However, approximately 90% of children with DTC will have lymph node metastasis and 50% of them are not detectable by preoperative ultrasonography and central compartment recurrence often precludes long-term cure [50, 51]. Thus, TT and central compartment lymph node dissection was recommended as part of the initial operation for most pediatric DTC. In addition, lateral compartment dissection with lymph node removal is indicated when lateral lymph node is involved.

RAI therapy has gained an increasing foothold in DTC treatment when properly applied after TT since more than 60 years ago [52]. In children and adolescents, RAI therapy is recommended for patients with neck metastasis, distant metastasis, extrathyroidal extension, vascular invasion or multifocal disease [8, 53, 54]. There are several cardinal advantages of RAI [55, 56]. First, RAI treatment may reduce the risk of recurrence and mortality. Second, RAI is administered orally and only one course of treatment is needed usually. Third, the ionizing radiation produced by ^{131}I irradiates the metastasis from inside to outside confined to a few millimeters in tissue. Finally, ^{131}I will be concentrated selectively and retained in the tumor even for small DTC metastases not detected by ultrasonography or MRI [57]. Of course, there are several cardinal disadvantages of RAI. Firstly, accumulation of RAI may be associated with an increased risk of pulmonary fibrosis and second primary malignancies [58]. Secondly, RAI use is still controversial especially for low-risk patients. Based on the majority of pediatric patients with DTC are advanced at presentation, it is suggested that most children should be treated with RAI to ablate residual disease and reduce the risk of disease recurrence, morbidity and mortality.

TSH suppression with levothyroxine postoperatively in pediatric DTC is a standard therapy for it is well recognized that TSH suppression can improve survival and prolongs time to recurrence. Nevertheless children's behavior and learning may suffer from levothyroxine at high dosage and it is not clear whether complete suppression of TSH secretion confers benefit for low-risk patients [59].

Table 1 Surgical treatment of pediatric DTC

	PTC	FTC
TT	Any present Age < 15 y Radiation history Distant metastasis Bilateral nodularity Extrathyroidal extension Aggressive variant Tumor > 1 cm in diameter CLN metastasis	Any present Vascular invasive Metastatic cancer Bilateral nodularity Extrathyroidal extension Patient preference
HT	All present Age ≥ 15 y No radiation history No distant metastasis No CLN metastasis No extrathyroidal extension No aggressive variant Tumor < 1 cm in diameter	All present No vascular invasive No metastasis Unifocal No extrathyroidal extension
CND	CCLN positive CCLN indeterminate	CCLN positive
LND	LCLN positive or suspicious	LCLN positive

Table 1 DTC = differentiated thyroid carcinoma, PTC = papillary thyroid carcinoma, FTC = follicular thyroid carcinoma, TT = total thyroidectomy, CLN = cervical lymph node, HT = Hemithyroidectomy, CND = central neck dissection, CCLN = central cervical lymph node, LND = lateral neck dissection, LCLN = lateral cervical lymph node.

5. Prognosis

Despite the advanced presentation of pediatric DTC, long-term follow-up shows better diseases-specific survival than in adults. Survival over decades is common for children and 10-year survival closes to 100%, 30-year survival over 90% even with distant metastasis [49]. In a European study, the overall survival rate of pediatric DTC for more than years was 100% [44]. Similarly, in an American research for 1753 pediatric TC, patients with papillary thyroid cancer had 98% 5-y survival, 97% 15-y survival, and 91% 30-y survival. Patients with follicular carcinoma had 96% 5-y survival, 95% 15-y survival, and 92% 30-y survival [4]. However, recurrences after 30 years also have been reported after initial diagnosis and therapy in pediatric DTC. Therefore, the follow-up of children and

adolescents with DTC should be continued lifelong.

6. Follow-up

In the first five years after initial therapy the follow-up care should be taken twice yearly involves the assessment of thyroglobulin, T3, free T3, T4, free T4 and thyrotropic stimulating hormone, ultrasonography of the neck and wholebody radioiodine scans. Thereafter, annual measurement until disease free, with additional thyroid function testing 6 weeks following dosage of levothyroxine adjustment [60, 61]. Then the pertinent issue is whether a patient with TT and RAI therapy is disease free. If the stimulated thyroglobulin is undetectable, no disease is present in most patients. If the level is 0.1–2.0 µg/L 30% will have residual disease, if the level is 2.0 –10.0 µg /L it is likely that

residual disease is present, both of which follow-up neck ultrasonography is indicated.

7. Conclusions

Pediatric DTC, typically presents with lymph node metastases and is associated with relatively high recurrence rates, accounts for 95% all of cases of thyroid carcinoma. Although recurrence is common, the outcome is favorable when appropriately treated and long-term followed-up is performed. To minimize the risk of recurrence, total thyroidectomy, central compartment dissection, with or without lateral compartment dissection should be performed by a high-volume thyroid surgeon for most of primary and recurrent DTC patients in children and adolescents. Furthermore, suppression of serum TSH with levothyroxine, RAI therapy for remnant ablation and a long-term follow-up should be done for most pediatric DTC.

Acknowledgments

This work is supported by Clinical Research Special Foundation by Wu Jieping Medical Foundation (320.6750.12398). This work was also supported by the establishment of fast molecular detection techniques during the operation and clinical application model of laryngeal squamous cell carcinoma by Beijing children's hospital scientific research project (2012ZD01).

References

1. Jemal, A, Bray F, Center MM, Ferlay J, Ward E, Forman D. Global cancer statistics. *CA Cancer J Clin.* 2011; 61:69-90. DOI: [10.3322/caac.20107](https://doi.org/10.3322/caac.20107)
2. Xing, M., Molecular pathogenesis and mechanisms of thyroid cancer. *Nat Rev Cancer*, 2013. 13(3): p. 184-99. DOI: [10.1038/nrc3431](https://doi.org/10.1038/nrc3431)
3. Xing, M, B.R. Haugen, M. Schlumberger. Progress in molecular-based management of differentiated thyroid cancer. *Lancet.* 2013; 381:1058-1069. DOI: [10.1016/S0140-6736\(13\)60109-9](https://doi.org/10.1016/S0140-6736(13)60109-9)
4. Hogan AR, Zhuge Y, Perez EA, Koniaris LG, Lew JI, Sola JE. Pediatric thyroid carcinoma: incidence and outcomes in 1753 patients. *J Surg Res.* 2009; 156: 167-172. DOI: [10.1016/j.jss.2009.03.098](https://doi.org/10.1016/j.jss.2009.03.098)
5. Vergamini LB, Frazier AL, Abrantes FL, Ribeiro KB, Rodriguez-Galindo C. Increase in the incidence of differentiated thyroid carcinoma in children, adolescents, and young adults: a population-based study. *J Pediatr.* 2014; 164: 1481-1485. DOI: [10.1016/j.jpeds.2014.01.059](https://doi.org/10.1016/j.jpeds.2014.01.059)
6. Niedziela, M. Pathogenesis, diagnosis and management of thyroid nodules in children. *Endocr Relat Cancer.* 2006; 13: 427-453. DOI: [10.1677/erc.1.00882](https://doi.org/10.1677/erc.1.00882)
7. Stevens C, Lee JK, Sadatsafavi M, Blair GK. Pediatric thyroid fine-needle aspiration cytology: a meta-analysis. *J Pediatr Surg.* 2009; 44: 2184-2191. DOI: [10.1016/j.jpedsurg.2009.07.022](https://doi.org/10.1016/j.jpedsurg.2009.07.022)
8. Rivkees SA, Mazzaferri EL, Verburg FA, Reiners C, Luster M, Breuer CK, Dinauer CA, Udelsman R. The treatment of differentiated thyroid cancer in children: emphasis on surgical approach and radioactive iodine therapy. *Endocr Rev.* 2011; 32: 798-826. DOI: [10.1210/er.2011-0011](https://doi.org/10.1210/er.2011-0011)
9. Tuttle RM, Ball DW, Byrd D, Dilawari RA, Doherty GM, Duh QY, Ehya H, Farrar WB, Haddad RI, Kandeel F, Kloos RT, Kopp P, Lamonica DM, Loree TR, Lydiatt WM, McCaffrey JC, Olson JA Jr, Parks L, Ridge JA, Shah JP, Sherman SI, Sturgeon C, Waguespack SG, Wang TN, Wirth LJ. Thyroid carcinoma. *J Natl Compr Canc Netw.* 2010; 8: 1228-1274. <http://www.jnccn.org/content/8/11/1228.full>
10. Duffy BJ, Fitzgerald PJ. Thyroid cancer in childhood and adolescence: a report on 28 cases. *Cancer.* 1950; 3: 1018-1032. DOI: [10.1002/1097-0142\(1950\)3:6<1018::AID-CNCR2820030611>3.0.CO;2-H](https://doi.org/10.1002/1097-0142(1950)3:6<1018::AID-CNCR2820030611>3.0.CO;2-H)
11. Winship T, Rosvoll RV. A study of thyroid cancer in children. *Am J Surg.* 1961; 102:

- 747-752. [DOI: 10.1016/0002-9610\(61\)90578-5](https://doi.org/10.1016/0002-9610(61)90578-5)
12. Taylor AJ, Croft AP, Palace AM, Winter DL, Reulen RC, Stiller CA, Stevens MC, Hawkins MM. Risk of thyroid cancer in survivors of childhood cancer: results from the British Childhood Cancer Survivor Study. *Int J Cancer*. 2009; 125: 2400-2405. [DOI: 10.1002/ijc.24581](https://doi.org/10.1002/ijc.24581)
 13. Differentiated thyroid cancer: getting the complete picture. *Lancet*. 2013; 381: 964. [DOI: 10.1016/S0140-6736\(13\)60696-0](https://doi.org/10.1016/S0140-6736(13)60696-0)
 14. Tronko MD, Saenko VA, Shpak VM, Bogdanova TI, Suzuki S, Yamashita S. Age Distribution of Childhood Thyroid Cancer Patients in Ukraine After Chernobyl and in Fukushima After the TEPCO-Fukushima Daiichi NPP Accident. *Thyroid*. 2014; 24: 1547-1548. [DOI: 10.1089/thy.2014.0198](https://doi.org/10.1089/thy.2014.0198)
 15. Fridman M, Savva N, Krasko O, Mankovskaya S, Branovan DI, Schmid KW, Demidchik Y. Initial presentation and late results of treatment of post-chernobyl papillary thyroid carcinoma in children and adolescents of Belarus. *J Clin Endocrinol Metab*. 2014; 99: 2932-2941. [DOI: 10.1210/jc.2013-3131](https://doi.org/10.1210/jc.2013-3131)
 16. Miyakawa, M. Radiation exposure and the risk of pediatric thyroid cancer. *Clin Pediatr Endocrinol*. 2014; 23: 73-82. [DOI: 10.1297/cpe.23.73](https://doi.org/10.1297/cpe.23.73)
 17. Su YP, Niu HW, Chen JB, Fu YH, Xiao GB, Sun QF. Radiation dose in the thyroid and the thyroid cancer risk attributable to CT scans for pediatric patients in one general hospital of China. *Int J Environ Res Public Health*. 2014; 11: 2793-2803. [DOI: 10.3390/ijerph110302793](https://doi.org/10.3390/ijerph110302793)
 18. Richards ML. Familial syndromes associated with thyroid cancer in the era of personalized medicine. *Thyroid*. 2010; 20: 707-713. [DOI: 10.1089/thy.2010.1641](https://doi.org/10.1089/thy.2010.1641)
 19. Kondo T, Ezzat S, Asa SL. Pathogenetic mechanisms in thyroid follicular-cell neoplasia. *Nat Rev Cancer*. 2006; 6: 292-306. [DOI: 10.1038/nrc1836](https://doi.org/10.1038/nrc1836)
 20. Henke LE, Perkins SM, Pfeifer JD, Ma C, Chen Y, DeWees T, Grigsby PW. BRAF V600E mutational status in pediatric thyroid cancer. *Pediatr Blood Cancer*. 2014; 61: 1168-1172. [DOI: 10.1002/psc.24935](https://doi.org/10.1002/psc.24935)
 21. Abubaker J, Jehan Z, Bavi P, Sultana M, Al-Harbi S, Ibrahim M, Al-Nuaim A, Ahmed M, Amin T, Al-Fehaily M, Al-Sanea O, Al-Dayel F, Uddin S, Al-Kuraya KS. Clinicopathological analysis of papillary thyroid cancer with PIK3CA alterations in a Middle Eastern population. *J Clin Endocrinol Metab*. 2008; 93: 611-618. [DOI: 10.1210/jc.2007-1717](https://doi.org/10.1210/jc.2007-1717)
 22. Vasko V, Saji M, Hardy E, Kruhlak M, Larin A, Savchenko V, Miyakawa M, Isozaki O, Murakami H, Tsushima T, Burman KD, De Micco C, Ringel MD. Akt activation and localisation correlate with tumour invasion and oncogene expression in thyroid cancer. *J Med Genet*. 2004; 41: 161-170. [DOI: 10.1136/jmg.2003.015339](https://doi.org/10.1136/jmg.2003.015339)
 23. Zivaljevic V, Tausanovic K, Sipetic S, Paunovic I, Diklic A, Kovacevic B, Stojanovic D, Zivic R, Stanojevic B, Kalezic N. A case-control study of papillary thyroid cancer in children and adolescents. *Eur J Cancer Prev*. 2013; 22: 561-565. [DOI: 10.1097/CEJ.0b013e3283603494](https://doi.org/10.1097/CEJ.0b013e3283603494)
 24. Rossi ED, Straccia P, Martini M, Revelli L, Lombardi CP, Pontecorvi A, Fadda G. The role of thyroid fine-needle aspiration cytology in the pediatric population: an institutional experience. *Cancer Cytopathol*. 2014; 122: 359-367. [DOI: 10.1002/cncy.21400](https://doi.org/10.1002/cncy.21400)
 25. Grob F, Carrillo D, Martínez-Aguayo A, Zoroquain P, Solar A, Nicolaidis I, González H. Diagnostic yield of fine-needle aspiration cytology for the detection of thyroid cancer in pediatric patients. *Rev Med Chil*. 2014; 142: 330-335. [DOI: 10.4067/S0034-98872014000300007](https://doi.org/10.4067/S0034-98872014000300007)
 26. Cooper DS, Doherty GM, Haugen BR, Kloos RT, Lee SL, Mandel SJ, Mazzaferri EL, McIver B, Pacini F, Schlumberger M, Sherman SI, Steward DL, Tuttle RM. Revised American Thyroid Association management guidelines for patients with thyroid nodules and differentiated thyroid

- cancer. *Thyroid*. 2009; 19: 1167-1214. [DOI: 10.1089/thy.2009.0110](#)
27. Campanella P, Ianni F, Rota CA, Corsello SM, Pontecorvi A. Quantification of cancer risk of each clinical and ultrasonographic suspicious feature of thyroid nodules: a systematic review and meta-analysis. *Eur J Endocrinol*. 2014; 170: 203-211. [DOI: 10.1530/EJE-13-0995](#)
 28. Lyshchik A, Drozd V, Demidchik Y, Reiners C. Diagnosis of thyroid cancer in children: value of gray-scale and power doppler US. *Radiology*. 2005; 235: 604-613. [DOI: 10.1148/radiol.2352031942](#)
 29. Cooper DS, Doherty GM, Haugen BR, Kloos RT, Lee SL, Mandel SJ, Mazzaferri EL, McIver B, Sherman SI, Tuttle RM; American Thyroid Association Guidelines Taskforce. Management guidelines for patients with thyroid nodules and differentiated thyroid cancer. *Thyroid*. 2006; 16: 109-142. [DOI: 10.1089/thy.2006.16.109](#)
 30. Choi SH, Kim EK, Kwak JY, Kim MJ, Son EJ. Interobserver and intraobserver variations in ultrasound assessment of thyroid nodules. *Thyroid*. 2010; 20: 167-172. [DOI: 10.1089/thy.2008.0354](#)
 31. Wang CC, Friedman L, Kennedy GC, Wang H, Kebebew E, Steward DL, Zeiger MA, Westra WH, Wang Y, Khanafshar E, Fellegara G, Rosai J, Livolsi V, Lanman RB.. A large multicenter correlation study of thyroid nodule cytopathology and histopathology. *Thyroid*. 2011; 21: 243-251. [DOI: 10.1089/thy.2010.0243](#)
 32. Kim TH, Park YJ, Lim JA, Ahn HY, Lee EK, Lee YJ, Kim KW, Hahn SK, Youn YK, Kim KH, Cho BY, Park do J. The association of the BRAF(V600E) mutation with prognostic factors and poor clinical outcome in papillary thyroid cancer: a meta-analysis. *Cancer*. 2012; 118: 1764-1773. [DOI: 10.1002/cncr.26500](#)
 33. Givens DJ, Buchmann LO, Agarwal AM, Grimmer JF, Hunt JP. BRAF V600E does not predict aggressive features of pediatric papillary thyroid carcinoma. *Laryngoscope*. 2014; 124: E389-393. [DOI: 10.1002/lary.24668](#)
 34. Collins BJ, Chiappetta G, Schneider AB, Santoro M, Pentimalli F, Fogelfeld L, Gierlowski T, Shore-Freedman E, Jaffe G, Fusco A. RET expression in papillary thyroid cancer from patients irradiated in childhood for benign conditions. *J Clin Endocrinol Metab*. 2002; 87: 3941-3946. [DOI: 10.1210/jcem.87.8.8748](#)
 35. Fenton C, Anderson J, Lukes Y, Dinauer CA, Tuttle RM, Francis GL. Ras mutations are uncommon in sporadic thyroid cancer in children and young adults. *J Endocrinol Invest*. 1999; 22: 781-789. [DOI: 10.1007/BF03343644](#)
 36. Nikiforov YE, Otori NP, Hodak SP, Carty SE, LeBeau SO, Ferris RL, Yip L, Seethala RR, Tublin ME, Stang MT, Coyne C, Johnson JT, Stewart AF, Nikiforova MN. Impact of mutational testing on the diagnosis and management of patients with cytologically indeterminate thyroid nodules: a prospective analysis of 1056 FNA samples. *J Clin Endocrinol Metab*. 2011; 96: 3390-3397. [DOI: 10.1210/jc.2011-1469](#)
 37. Xing M. Prognostic utility of BRAF mutation in papillary thyroid cancer. *Mol Cell Endocrinol*. 2010; 321: 86-93. [DOI: 10.1016/j.mce.2009.10.012](#)
 38. Nikiforova MN, Nikiforov YE. Molecular diagnostics and predictors in thyroid cancer. *Thyroid*. 2009; 19: 1351-1361. [DOI: 10.1089/thy.2009.0240](#)
 39. Tufano RP, Bishop J, Wu G.. Reoperative central compartment dissection for patients with recurrent/persistent papillary thyroid cancer: efficacy, safety, and the association of the BRAF mutation. *Laryngoscope*. 2012; 122: 1634-1640. [DOI: 10.1002/lary.23371](#)
 40. Kumagai A, Namba H, Saenko VA, Ashizawa K, Ohtsuru A, Ito M, Ishikawa N, Sugino K, Ito K, Jeremiah S, Thomas GA, Bogdanova TI, Tronko MD, Nagayasu T, Shibata Y, Yamashita S. Low frequency of BRAFT1796A mutations in childhood thyroid carcinomas. *J Clin Endocrinol Metab*. 2004; 89: 4280-4284. [DOI: 10.1210/jc.2004-0172](#)

41. McLeod DS, Sawka AM, Cooper DS. Controversies in primary treatment of low-risk papillary thyroid cancer. *Lancet*. 2013; 381: 1046-57. [DOI: 10.1016/S0140-6736\(12\)62205-3](https://doi.org/10.1016/S0140-6736(12)62205-3)
42. Carty SE, Cooper DS, Doherty GM, Duh QY, Kloos RT, Mandel SJ, Randolph GW, Stack BC Jr, Steward DL, Terris DJ, Thompson GB, Tufano RP, Tuttle RM, Udelsman R. Consensus statement on the terminology and classification of central neck dissection for thyroid cancer. *Thyroid*. 2009; 19: 1153-1158. [DOI: 10.1089/thy.2009.0159](https://doi.org/10.1089/thy.2009.0159)
43. Raval MV, Bentrem DJ, Stewart AK, Ko CY, Reynolds M. Utilization of total thyroidectomy for differentiated thyroid cancer in children. *Ann Surg Oncol*. 2010; 17: 2545-2553. [DOI: 10.1245/s10434-010-1083-3](https://doi.org/10.1245/s10434-010-1083-3)
44. Dzodic R, Buta M, Markovic I, Gavrilovic D, Matovic M, Djuriscic I, Milovanovic Z, Pupic G, Tasic S, Besic N. Surgical management of well-differentiated thyroid carcinoma in children and adolescents: 33 years of experience of a single institution in Serbia. *Endocr J*. 2014; 61: 1079-1086. [DOI: 10.1507/endocrj.EJ14-0226](https://doi.org/10.1507/endocrj.EJ14-0226)
45. Antonelli A, Fallahi P, Grosso M, Boni G, Minuto MN, Miccoli P. Lobectomy versus total thyroidectomy in children with post-Chernobyl thyroid cancer: a 15 year follow-up. *Endocrine*. 2011; 40: 432-436. [DOI: 10.1007/s12020-011-9500-3](https://doi.org/10.1007/s12020-011-9500-3)
46. Udelsman R. Thyroid cancer surgery. *Rev Endocr Metab Disord*. 2000; 1: p. 155-163. [DOI: 10.1023/A:1010022913415](https://doi.org/10.1023/A:1010022913415)
47. Sosa JA, Bowman HM, Tielsch JM, Powe NR, Gordon TA, Udelsman R. The importance of surgeon experience for clinical and economic outcomes from thyroidectomy. *Ann Surg*. 1998; 228: 320-330. [DOI: 10.1097/00000658-199809000-00005](https://doi.org/10.1097/00000658-199809000-00005)
48. Miller BS, Doherty GM. An examination of recently revised differentiated thyroid cancer guidelines. *Curr Opin Oncol*. 2011; 23: 1-6. [DOI: 10.1097/CCO.0b013e32833fc9c4](https://doi.org/10.1097/CCO.0b013e32833fc9c4)
49. Hay ID, Gonzalez-Losada T, Reinalda MS, Honetschlager JA, Richards ML, Thompson GB. Long-term outcome in 215 children and adolescents with papillary thyroid cancer treated during 1940 through 2008. *World J Surg*. 2010; 34: 1192-1202. [DOI: 10.1007/s00268-009-0364-0](https://doi.org/10.1007/s00268-009-0364-0)
50. Doherty GM. Prophylactic central lymph node dissection: continued controversy. *Oncology (Williston Park)*. 2009; 23: 603-608.
51. Bonnet S, Hartl D, Leboulleux S, Baudin E, Lombroso JD, Al Ghuzlan A, Chami L, Schlumberger M, Travagli JP. Prophylactic lymph node dissection for papillary thyroid cancer less than 2 cm: implications for radioiodine treatment. *J Clin Endocrinol Metab*. 2009; 94: 1162-1167. [DOI: 10.1210/jc.2008-1931](https://doi.org/10.1210/jc.2008-1931)
52. Coliez R, Tubiana M, Dutreix J, Guelfi J. Results of examination of 85 cases of cancer of the thyroid with radioactive iodine. *J Radiol Electrol Arch Electr Medecale*. 1951; 32: 881-895.
53. Pawelczak M, David R, Franklin B, Kessler M, Lam L, Shah B. Outcomes of children and adolescents with well-differentiated thyroid carcinoma and pulmonary metastases following ¹³¹I treatment: a systematic review. *Thyroid*. 2010; 20: 1095-1101. [DOI: 10.1089/thy.2009.0446](https://doi.org/10.1089/thy.2009.0446)
54. Handkiewicz-Junak D, Wloch J, Roskosz J, Krajewska J, Kropinska A, Pomorski L, Kukulska A, Prokurat A, Wygoda Z, Jarzab B. Total thyroidectomy and adjuvant radioiodine treatment independently decrease locoregional recurrence risk in childhood and adolescent differentiated thyroid cancer. *J Nucl Med*. 2007; 48: 879-888. [DOI: 10.2967/jnumed.106.035535](https://doi.org/10.2967/jnumed.106.035535)
55. Verburg FA, Biko J, Diessl S, Demidchik Y, Drozd V, Rivkees SA, Reiners C, Häscheid H. I-131 activities as high as safely administrable (AHASA) for the treatment of children and adolescents with advanced differentiated thyroid cancer. *J Clin Endocrinol Metab*. 2011; 96: E1268-1271. [DOI: 10.1210/jc.2011-0520](https://doi.org/10.1210/jc.2011-0520)
56. Markovina S, Grigsby PW, Schwarz JK, DeWees T, Moley JF, Siegel BA, Perkins SM. Treatment approach, surveillance, and

- outcome of well-differentiated thyroid cancer in childhood and adolescence. *Thyroid*. 2014; 24: 1121-1126. [DOI: 10.1089/thy.2013.0297](https://doi.org/10.1089/thy.2013.0297)
57. Rivkees SA, Mazzaferri EL, Verburg FA, Reiners C, Luster M, Breuer CK, Dinauer CA, Udelsman R. The treatment of differentiated thyroid cancer in children: emphasis on surgical approach and radioactive iodine therapy. *Endocr Rev*. 2011; 32: 798-826. [DOI: 10.1210/er.2011-0011](https://doi.org/10.1210/er.2011-0011)
58. Hebestreit H, Biko J, Drozd V, Demidchik Y, Burkhardt A, Trusen A, Beer M, Reiners C. Pulmonary fibrosis in youth treated with radioiodine for juvenile thyroid cancer and lung metastases after Chernobyl. *Eur J Nucl Med Mol Imaging*. 2011; 38: 1683-1690. [DOI: 10.1007/s00259-011-1841-x](https://doi.org/10.1007/s00259-011-1841-x)
59. Rivkees, S.A., Pediatric Graves' disease: controversies in management. *Horm Res Paediatr*. 2010; 74: 305-311. [DOI: 10.1159/000320028](https://doi.org/10.1159/000320028)
60. Hung W, Sarlis NJ. Current controversies in the management of pediatric patients with well-differentiated nonmedullary thyroid cancer: a review. *Thyroid*. 2002; 12: 683-702. [DOI: 10.1089/105072502760258668](https://doi.org/10.1089/105072502760258668)
61. Waguespack SG, Francis G. Initial management and follow-up of differentiated thyroid cancer in children. *J Natl Compr Canc Netw*. 2010; 8: 1289-1300.